

## Histopathological Effects of Ageratum Leaf Extract (*Ageratum Conyzoides*) on Wound Healing Acceleration After Acute Excisional Wound on Epidermis in Type 2 Diabetes Mellitus Model of Sprague Dawley Rats (*Rattus norvegicus*)

Liliek Yudhantoro, Nucki Nursjamsi Hidajat, Yoyos Dias Ismiarto, Darmadji Ismono  
Department of Orthopaedics and Traumatology, Faculty of Medicine Universitas Padjadjaran  
Dr. Hasan Sadikin General Hospital Bandung

### Abstract

Diabetic wound healing problem often occurs if proper care is not given which will lead to the development of a chronic wound. *Ageratum (Ageratum conyzoides L.)* leaves is one of the most common plants in tropical areas, including Indonesia, which are frequently used in traditional treatment due to its anti-bacterial properties. This experimental study aimed to identify the effects of topical application of *Ageratum* leaf extract on wound healing based on histopathological examination of the reepithelization, ulceration, neovascularization, and the presence of inflammatory cells. This study was performed in the period of September to December 2017 at the Pharmacology and Pathology Anatomy laboratories of Dr. Hasan Sadikin General Hospital Bandung, Indonesia. Excisions were made on the back of the 36 rats that were divided into control and test groups. The test group then received a topical application of *Ageratum* leaf extract. The resulting histopathologic appearance of the wound was then examined. The test group showed better wound healing in all parameters inspected when compared to the control group. Mann-Whitney Test with 95% confidence interval ( $p < 0.05$ ) showed that the re-epithelialization, ulceration, neovascularization, and presence of inflammatory cells reflected a statistically significant improvement in the test group ( $p = 0.319$ ,  $p = 0.290$ ,  $p = 0.251$ , and  $p = 0.245$ , respectively). This study concludes that the topical application of *Ageratum* leaf extract has a statistically significant benefit on diabetic wound healing.

**Key words:** *Ageratum* leaves, diabetic wound, wound healing

## Pengaruh Histopatologis Ekstrak Daun Ageratum (*Ageratum Conyzoides*) terhadap Akselerasi Penyembuhan Luka Setelah Luka Eksisi Akut pada Epidermis Model 2 Diabetes Mellitus Tikus Sprague Dawley (*Rattus norvegicus*)

### Abstrak

Luka diabetes sering menyebabkan luka kronik jika tidak mendapat penanganan yang tepat. *Ageratum (Ageratum conyzoides)* merupakan tanaman khas daerah tropis termasuk Indonesia, yang daunnya digunakan untuk pengobatan tradisional karena mengandung zat anti bakteri. Penelitian eksperimental ini menggunakan desain kelompok kontrol post-test untuk mengidentifikasi efek aplikasi topical dari ekstrak daun *Ageratum* pada penyembuhan luka dengan pemeriksaan histopatologis dari reepitelialisasi, ulserasi, neovaskularisasi, dan sel radang. Penelitian ini dilakukan antara September hingga Desember 2017 di laboratorium Farmakologi dan Patologi Anatomi Rumah Sakit Umum Dr. Hasan Sadikin Bandung. Eksisi dilakukan pada tiap-tiap tikus dari 36 tikus yang dibagi menjadi kelompok kontrol dan kelompok uji di mana kelompok uji dilakukan perawatan dengan ekstrak etanol daun *ageratum* secara topikal. Setelah diaplikasikan ekstrak daun *Ageratum*, luka diperiksa secara histopatologi. Observasi pada kelompok uji menunjukkan penyembuhan luka eksisional tikus diabetes yang lebih baik daripada kelompok kontrol untuk semua parameter. Uji Mann-Whitney dengan interval kepercayaan 95% ( $p < 0,05$ ) menunjukkan bahwa nilai  $p$  untuk reepitelisasi, ulserasi, neovaskularisasi, dan sel radang adalah  $p = 0,319$ ,  $p = 0,290$ ,  $p = 0,251$ , dan  $p = 0,245$ . Aplikasi topikal dari ekstrak daun *Ageratum* memiliki manfaat pada penyembuhan luka diabetes dan hasilnya signifikan secara statistik.

**Kata kunci:** Daun *ageratum*, luka diabetes, penyembuhan luka

**Corresponding Author:** Liliek Yudhantoro, Department of Orthopaedics and Traumatology, Faculty of Medicine Universitas Padjadjaran/Dr. Hasan Sadikin General Hospital Bandung, Jalan Pasteur No. 38 Bandung, West Java, Indonesia, Email: [yudhantoro@icloud.com](mailto:yudhantoro@icloud.com)

## Introduction

Patients with diabetes mellitus often complain of open wounds that are difficult to heal. Diabetic Mellitus and its resulting diabetic wounds cause a burden in terms of quality of life and health care cost in many instances and thus require significant attention in the treatment. Alternative medicine that is cost-effective and easy to obtain could help solving this problem.<sup>1</sup> Ageratum, which is a well-known plant in several regions in Indonesia that is often used as a traditional medicine for wounds, is divided into two species: *Ageratum latifolium* and *Ageratum conyzoides*.<sup>2</sup> Ageratum leaves can be found in the tropics or subtropics. Based on the traditional treatment experiences in the communities that use Ageratum leaves for wound care as well as studies on the effects of Ageratum leaves on wound care in diabetic patients, efforts have been made to study the effects of Ageratum leaves on open wounds and its use in diabetic patients.

A study conducted by Mustafa et al. has investigated the component of Ageratum leaves but did not apply the leaves directly to see the effect on wound healing in vivo. Rahman et al. did an experimental study in 2012 to explore the wound healing properties of Ageratum on acute open wound healing in non-diabetic rats.<sup>3</sup> A study by Oladejo and Imosemi showed that *Ageratum conyzoides* contains phytochemical substances that can facilitate the healing of acute open wounds.<sup>4</sup> In Prasad's research on Ageratum leaf extract for the healing of acute wounds in experimental mice, *Ageratum conyzoides* was able to improve tissue regeneration.<sup>5</sup> While previous studies only investigated the components of Ageratum leaves and their effect on healthy mice's wound healing, this study aimed to analyze the effect of Ageratum leaves to treat open wound in diabetic mice model.

A study conducted by Nyunaiet al. in 2015 has shown that *Ageratum conyzoides* possess the ability to release insulin by stimulating the regeneration process.<sup>6</sup> Based on the abovementioned previous studies, it can be concluded that the Ageratum leaf extract has been proved to be successful in curing acute wound in non-diabetic rats.<sup>10</sup> This study intended to investigate the use of Ageratum leaf extract to heal acute wounds of the epidermal layer in diabetic model rats. The result of this study could provide a promising answer towards the application of these leaves in the treatment

of acute epidermal wounds in patients with diabetes mellitus.<sup>11-13</sup>

## Methods

This experimental study with post-test-only control group design aimed to identify the effect of topical application of Ageratum leaf extract on wound healing by examining the histopathological appearance of re-epithelialisation, ulceration, neovascularization, and the presence of inflammatory cells. The ethical aspect of this study has been approved through the issuance of the ethical clearance number: LB.02.01/X.2.2.1/9163/2017. The study was performed between September and December 2017 at the Pharmacology and Pathology Anatomy laboratories of Dr. Hasan Sadikin General Hospital Bandung, Indonesia. The Sprague-Dawley rats were induced to a diabetic state by injecting alloxan monohydrate solution 50mg/kg body weight diluted in 10mM sodium citrate with pH 4.5. These diabetic model rats were randomized into test and control groups. Excisions were made on the back of the 36 in the form of 2cm x 2cm wide excision made using uniform stencil. After antiseptic procedure was done, full skin thickness excision was created using a scalpel. The test group received the topical application of Ageratum leaf ethanol extract once a day while the control group was only treated with normal saline irrigation.

The dried powder of Ageratum leaves was extracted using methanol in Soxhlet extractor for 8 hours. The extract was then concentrated in a rotary flash evaporator (Rotavapour) for 24 hours. The concentrated extract was subsequently evaporated in a vacuum oven with a temperature higher than 50°C. The dry extract produced weighed  $\pm 13.3\%$  of the original weight and was then kept in a tight sealed bottle at 2-80°C. Two grams of Ageratum ethanol extract were then mixed in 100 grams of CMC Na 0.5% gel to make 2% gel solution to ease the application process.

On the seventh day of the Ageratum extract gel application to the wound, the wound tissue was harvested, outstripping 1 cm beyond the tissue margin to ensure all the granulation tissue was collected. Preserved harvested tissue (using 10% formalin solution) was incorporated into a paraffin block and sliced using a microtome into 4-inch-thick slices. These slices then underwent hematoxylin-eosin dyeing. A single

anatomical pathologist blindly evaluated the histopathological features of the tissue using a light microscope. The histologic features were grouped based on the re-epithelialization, ulceration, neovascularization, presence of inflammatory cells, and granulation maturation. Ultimately, the total score of the wound healing process were calculated based on the scoring system depicted in Table 1 below. Obtained data were tested using the SPSS version 19.0 computer program.

### Discussion

This study generally shows that the application of topical Ageratum leaf extract in acute excisional wounds of diabetic models can accelerate the epithelialization process. This epithelialization process is influenced by an

increase in the number of fibroblasts. The same result was shown in collagen formation which revealed an increase in collagen thickness on day 3 (inflammatory phase), which served as the main structure of the new extracellular matrix of wound tissue and decreased on the 10th day (proliferation phase). From these results, it can be seen that Ageratum leaf extract can increase the collagen thickness in the inflammatory phase but reduce the thickness of collagen during the proliferation phase.

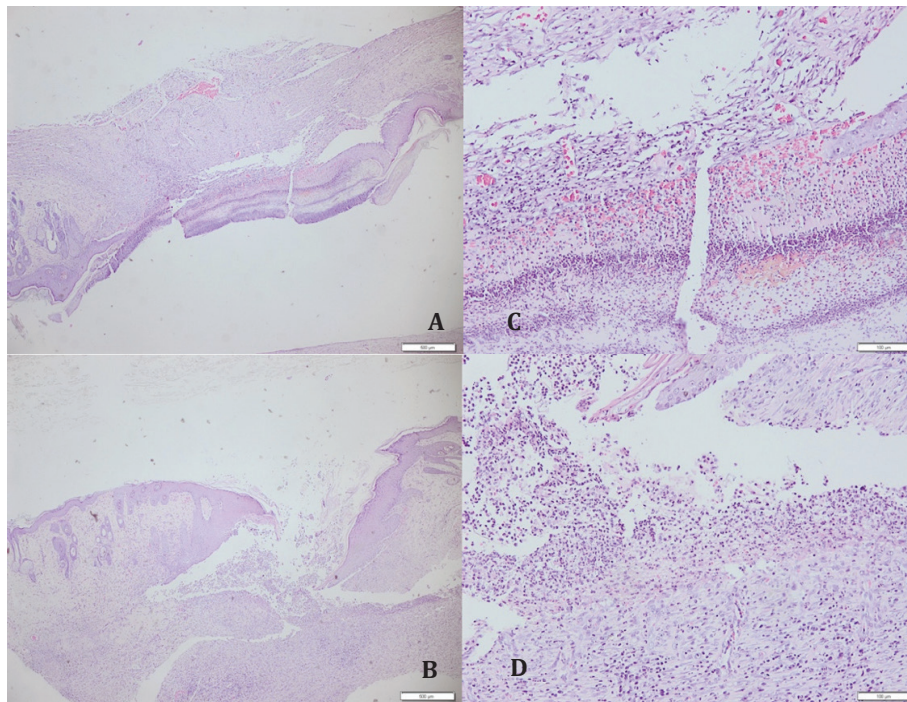
Table 2 shows that all control rats were categorized into the re-epithelialization 0 group while in the treatment group only 1 (12.5%) was classified in the re-epithelialization 0 group and 7 (87.5%) rats were categorized into the re-epithelialization 1 group. In the control group, 6 (75%) rats were categorized into ulceration 0 group, and 2 (25%) rats were categorized into ulceration 1 group while in the treatment

**Table 1 Histopathologic score to assess wound healing (cited from “Effects of Systemic Erythropoietin on Ischemic Wound Healing in Rats”<sup>16</sup>)**

Scoring criteria	Score			
	0	1	2	3
Re-epithelialisation	None	Partial	Complete, but immature or thin	Complete and mature
Neovascularisation	None	Up to 5 vessels/HMF	6-10 vessels/HMF	>10 vessels/HMF
Amount of granulation tissue	None	Scant	Moderate	Abundant
Maturation of granulation tissue	Immature	Mild maturation	Moderate maturation	Fully matured
Inflammatory cells	None	Scant	Moderate	Abundant
Ulcer	Wide and deep ulcers, abscesses	Wide ulcers	None or very small	None

**Table 2 Comparison between Re-epithelization and Ulceration in Control and Treatment Groups**

Variable	Group		P value
	Control n=8	Treatment n=8	
Reepithelization			0.001**
0	8 (100.0%)	1 (12.5%)	
1	0 (0.0%)	7 (87.5%)	
Ulcers			0.041**
0	6 (75.0%)	1 (12.5%)	
1	2 (25.0%)	7 (87.5%)	



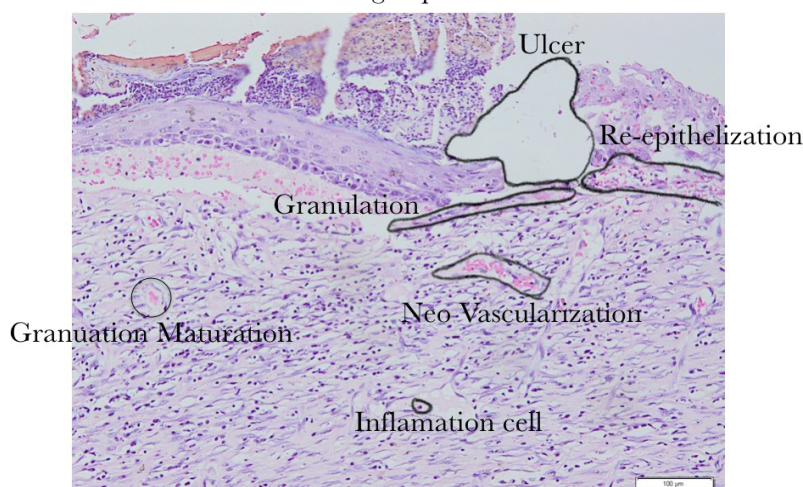
**Figure 1** Histologic Appearance of Wound from Control Group in 20x (A) and 100x Magnification, and from Treatment Group in 20x (C) and 100x (D) Magnification

group, only 1 (12,5%) rat was categorized into ulceration 0 group and 7 (87.5%) rats were categorized into ulceration 1 group. Table 2 showed that there were significant differences ( $p < 0.05$ ) in the re-epithelialization and ulceration between the two groups. Table 3 shows that in the control group, 2 (25%) rats were categorized

into neovascularization 0 group and 6 (75%) rats were categorized into neovascularization 2 group. Meanwhile, in the treatment group, there was 1 (12.5%) rat in the neovascularization 0 group, 1 (12.5%) rat in the neovascularization 1 group, 2 (25%) rats in the neovascularization 2 group, and 4 (50%) rats in the neovascularization

**Table 3** Comparison between Neovascularization and Presence of Inflammatory Cells in Control and Treatment Groups

Variable	Group		p value
	Control n=8	Treatment n=8	
Neovascularization			0.270
0	2 (25.0%)	1 (12.5%)	
1	0 (0.0%)	1 (12.5%)	
2	6 (75.0%)	2 (25.0%)	
3	0 (0.0%)	4 (50.0%)	
Inflammatory cells			0.001**
0	1 (12.5%)	0 (0.0%)	
1	1 (12.5%)	0 (0.0%)	
2	6 (75.0%)	0 (0.0%)	
3	0(0.0%)	8(100.0%)	



**Figure 2 Histologic Appearance of Wound from Control Group in 100x Magnification**

3 group. In the control group, 1 (12.5%) rat was categorized into inflammatory cell 0 group, 1 (12.5%) rat was categorized into inflammatory cell 1 group, and 6 (75%) rats were categorized into inflammatory cell 2 group. In the treatment group, all rats were categorized into the inflammatory cell 3 group. As shown in Table 3,

it can be concluded that there were no significant differences in neovascularization between the two groups whereas significant differences in inflammatory cells produced were seen between the two groups.

Previous studies only investigated the component of Ageratum leaves but did not apply

**Table 4 Comparison between Granulation Network and Granulation Maturation in Control and Treatment Groups**

Variable	Group		Value p
	Control n=8	Treatment n=8	
Granulation tissue			0.001**
0	2 (25.0%)	0 (0.0%)	
1	6 (75.0%)	0 (0.0%)	
2	0 (0.0%)	6 (75.0%)	
3	0 (0.0%)	2 (25.0%)	
Mature granulation			0.001**
0	3 (37.5%)	0 (0.0%)	
1	5 (62.5%)	0 (0.0%)	
2	0 (0.0%)	6 (75.0%)	
3	0 (0.0%)	2 (25.0%)	

**Table 5 Comparison between Total Scores of Control and Treatment Groups**

Variable	Group		Value P
	Control N=8	Treatment N=8	
Total score			0.000**
Mean±Std	4.75±1.832	11.37±1.407	
Median	5.000	11.500	
Range (min-max)	1.00-7.00	9.00-13.00	

the leaves directly to see the effect on wound healing in vivo, while this study examined the application of Ageratum leaves on acute open wound healing.<sup>14</sup> Rahman et al. did an experimental study in 2012 to explore the wound healing properties of Ageratum on acute open wound healing in non-diabetic rats while this study tested the application of Ageratum leaves in diabetic rats.<sup>15</sup> Table 5 shows a statistically significant difference in the total variable score between the control and treatment groups. The analysis showed an increase in the overall score of the treatment group.

Ageratum leaf extract carries high antioxidant activities because it contains a high amount of polyphenols. The polyphenol contained in Ageratum leaves is ellagic acid. Ellagic acid has been observed to have a fibroblast synthesis stimulating property. Fibroblasts are the principal cells during the proliferation phase of wound healing that play a major role in providing extracellular matrix as a framework for keratinocyte migration. Dense fibroblasts assist the formation of denser and more compact extracellular matrices so that the epithelialization process by keratinocytes is triggered. The thicker collagen layer observed in the treatment group was presumably caused by the increase in fibroblasts and led to faster re-epithelialization when compared to the control group. In this study, no analytical statistic was performed to compare the size of the epithelialization of the wound between the control and the treatment groups.

In a previous study conducted by Oladejo and Imosemi, it was found that Ageratum conyzoides contained phytochemicals which could shorten the healing time of acute open wounds. The wound healing process in the treatment group went aptly in this study because Ageratum leaf extract was shown to accelerated epithelialization process. Other study conducted by Prasad also showed that Ageratum conyzoides application to open wound in rat is able to increase tissue regeneration. Rahan et al. found that Ageratum conyzoides extract contains anti-inflammatory properties by inhibiting the synthesis and release of inflammatory mediators such as prostaglandin, histamine, and serotonin. The substances that are suspected to be responsible for this anti-inflammatory effect are quercetin, kaempferol, glycosides, tannins, and phenols.<sup>7-9</sup> These findings were not shown in the current study where the inflammatory cells were found to be statistically more abundant in the control group when compared to the treatment

group.

This experiment shows that Ageratum leaf extract might accelerate the healing of acute open wounds in diabetes patients. Topical administration of Ageratum leaf extract stimulates the healing process of excisional wounds in type II diabetes mellitus models by increasing the thickness of collagen in the inflammatory phase and decreases collagen thickness in the proliferation phase during the healing of excisional wounds and accelerates epithelialization in type II diabetes mellitus models.

## References

1. Soelistijo SA, Novida H, Rudijanto A, Soewondo P, Suastik Ka, Manaf A, et al. Konsensus pengelolaan dan pencegahan diabetes melitus tipe 2 di Indonesia. Jakarta: PB Perkeni; 2015
2. Rahmawati N, Kuswandi M. Cytotoxic effect of ethanolic extract of *ageratum conyzoides*, l against hela cell line. International Conference: Research and Application on Traditional Complementary and Alternative Medicine in Health Care (TCAM); 2012 June, 22<sup>nd</sup>-23<sup>rd</sup>; Surakarta: TCAM. 2015. p. 48-50.
3. Rahman MA, Akter N, Rashid H, Ahmed NU, Uddin N, Islam MS. Analgesic and anti-inflammatory effect of whole *Ageratum conyzoides* and *Emilia sonchifolia* alcoholic extracts in animal models. *African J Pharm Pharmacol.* 2012;6(20):1469-76.
4. Nyunad' N, Abdennebi E, Bickii J, Manguelle-Dicoum M. Subacute antidiabetic properties of *Ageratum conyzoides* leaves in diabetic rats. *Inter J Pharmac Sci Res.* 2015;6(4): 1378-87.
5. Hassan MM, Shahid-Ud-Daula A, Jahan IA, Nimmi I, Adnan T, Hossain H. Anti-inflammatory activity, total flavonoids and tannin content from the ethanolic extract of *ageratum conyzoides* linn. leaf. *Int J Pharm Phytopharmacol Res.* 2012;1(5):234-41.
6. Mitra PK. Antibacterial activity of an isolated compound (ac-1) from the leaves of *ageratum conyzoides* linn. *J Med Plants Studies.* 2013;1(3):145-50.
7. Odeleye O, Oluyeye J, Aregbesola O, Odeleye P. Evaluation of preliminary phytochemical and antibacterial activity of *Ageratum conyzoides* (L.) on some clinical bacterial isolates. *Int J Eng Sci.* 2014;3:1-5.
8. Ashande MC, Mpiana PT, Koto-te-Nyiwa

- N. Ethno-botany and pharmacognosy of *ageratum conyzoides* l (compositae). *J Advan Med Life Sci.* 2015;2(4):1-6.
9. Agbafor KN, Engwa AG, Obiudu IK. Analysis of chemical composition of leaves and roots of *ageratum conyzoides*. *Int J Cur Res Acad Rev.* 2015;3(11):60-5.
  10. Bosi CF, Rosa DW, Grougnet R, Lemonakis N, Halabalaki M, Skaltsounis AL, et al. Pyrrolizidine alkaloids in medicinal tea of *Ageratum conyzoides*. *Brazilian J Pharmacogn.* 2013;23(3):425-32.
  11. Kaur R, Kaur S. Anxiolytic potential of methanol extract from *ageratum conyzoides* linn leaves. *Pharmacognosy J.* 2015;7(4): 236-41.
  12. Okémy NA, Moussoungou AS, Koloungous B, Abena AA. Topical Anti-inflammatory effect of aqueous extract ointment of *Ageratum conyzoides* L. In rat wistar. *Int J Phytopharm.* 2015;5(3):37-41.
  13. Nasrin F. Antioxidant and cytotoxic activities of *Ageratum conyzoides* stems. *Int Cur Pharma.* 2013;2(2):33-7.
  14. Kouame BK, Toure D, Kablan L, Bedi G, Tea I, Robins R, Chalchat JC, Tonzibo F. Chemical constituents and antibacterial activity of essential oils from flowers and stems of *Ageratum conyzoides* from Ivory coast. *Rec Nat Prod.* 2018;12(2):160-8.
  15. Nasar I, Endardjo S, Handjari D, Kurniawan A, Mudigdo A, Dewayani B, et al. Pedoman penanganan bahan pemeriksaan untuk histopatologi. Jakarta: Perhimpunan Dokter Spesialis Patologi Indonesia (IAPI); 2018.
  16. Arslantaş MK, Arslantaş R, Tozan EN. Effects of systemic erythropoietin on ischemic wound healing in rats. *Ostomy Wound Manage.* 2015;61(3):28-33.